

Esthetic Treatment Planning for Orthognathic Surgery

G. WILLIAM ARNETT, DDS
MICHAEL J. GUNSON, DDS, MD

When planning treatment for the correction of dentofacial deformities, facial and airway needs should be addressed concurrently with occlusal correction. In this article, we will briefly examine the three steps involved in our analytical approach to occlusal correction: orthodontic preparation, facial examination, and esthetic cephalometric treatment planning.* We will refer specifically to facial diagnosis and treatment planning, but these principles also apply to the treatment of obstructive sleep apnea. What treats the face generally treats the airway as well.

Step 1: Orthodontic Preparation

Orthodontic Incisor Positioning

Orthodontic incisor inclinations have a significant effect on the nasal base and chin projection obtained with orthognathic surgery. Dental and facial discrepancies are often disproportionate because of dental compensations to the anteroposterior skeletal misalignment. These dental compensations involve axial inclination changes of the incisors in response to increased or decreased overjet. An example is mandibular retrusion: the maxillary incisors are often upright, whereas the mandibular incisors are flared anteriorly in response to the Class II skeletal and dental relationships.

To produce optimal facial esthetics, orthodontic mechanics should remove dental compensations prior to orthognathic surgery. The mandibular incisors are ideally placed from 61-68° to the mandibular occlusal plane and the maxillary incisors at 54-60° to the maxillary occlusal plane. Attempting orthodontic overjet correction and then resorting to surgery without decompensating the incisors produces extremely poor facial results. For instance, treating a skeletal mandibular retrusion

with maxillary first premolar extractions, headgear, and Class II elastics will cause the maxillary incisors to upright and the mandibular incisors to flare. If surgery is then performed with these dental compensations present, the nasal base may be too prominent and the chin too recessive.

In summary, when determining the incisor positioning needs for treatment, all factors—crowding, periodontal needs, lip and facial support, and airway implications—should be considered. Generally speaking, all dental compensations should be removed prior to surgery.

Orthodontic Premolar/Molar Positioning

The best recommendation for buccal segment control is to keep the teeth and roots in the alveolar bone without dental expansion or labial crown torque. Segmental maxillary surgery can manage archform and arch-width issues without the risk of dental relapse or periodontal decline associated with orthodontic expansion of the maxillary posterior segments. Excessive orthodontic buccal crown torque, in particular, can lead to complications in orthognathic surgery. Multisegment surgical uprighting of excessive posterior buccal crown torque may result in unpredictable and excessive flaring of the nasal base. In the case shown in Figure 1, the second molar surgical expansion was 0mm, yet the skeletal expansion at the palatal level was 8mm. The preoperative orthodontic setup of this patient demonstrates significant buccal crown torque of the posterior segments, which required surgical uprighting and produced unesthetic nasal base expansion and protrusion.

The posterior segments provide fullness to the smile by filling the buccal corridors. Clinicians often speak of unesthetic black triangles in this area, but expanding the maxilla to fill the buccal corridors may not be the complete answer. The black triangles not only result from a narrow transverse dimension, but are more often associated with maxillary retrusion and/or a steep occlusal plane. Maxillary retrusion makes the arch widest

*Editor's Note: In next month's issue, Dr. Dipak Chudasama will interview Drs. Arnett and Gunson on specific applications of their esthetic planning technique and the advantages and disadvantages of particular orthognathic surgeries.

Drs. Arnett and Gunson are specialists in orthognathic surgery and research in private practice at The Center for Corrective Jaw Surgery, 9 E. Pedregosa St., Santa Barbara, CA 93101. E-mail: arnett@arnettgunson.com and gunson@arnettgunson.com.



Dr. Arnett



Dr. Gunson

posterior to the commissures, thus producing the black triangles. Additionally, with a steep occlusal plane, the molars and premolars are not visible at full smile. In Figure 2, the patient's buccal corridors were open, showing black triangles, and were filled only with orthodontic brackets. The treatment plan was for bimaxillary advancement with counterclockwise rotation. The result placed the posterior segments in a more esthetic (visible) anterior and inferior position relative to the commissures, producing an esthetic, full smile without any surgical maxillary expansion.

Step 2: Facial Examination

Facial examination should be simple yet comprehensive, always considering the airway in the process. In general, facial needs correlate with airway needs.

Because x-rays and photographs may represent the patient's face inaccurately, the most important component of a proper facial esthetic analysis is direct, clinical facial measurement. Examination should involve standardized clinical posturing of the patient, including natural head posture, centric relation (with the uppermost condyle position at first tooth contact), and relaxed lip posture. In this way, actual soft-tissue/hard-tissue relationships can be visualized and recorded in all three planes of space.

Natural head posture is the orientation the patient assumes when looking at his or her own pupils in a mirror, an object on the horizon, or someone exactly the same height: the head is neither up nor down. Patients do not carry their heads with Frankfort horizontal parallel to the floor; therefore, Frankfort horizontal should not dictate the head posture used for facial treatment planning. All examination data should be recorded in centric relation, given that orthodontic and surgical results are evaluated relative to this position for proper function. The patient should also be in the relaxed lip position, since it shows the soft tissue relative to hard tissue without muscular compensation for dentoskeletal abnormalities. Vertical disharmony between lip lengths and skeletal height cannot be assessed unless the lips are relaxed.

As with cephalometric analyses, hundreds of facial soft-tissue traits have been proposed and studied. Selection of a trait for facial examination should depend on a high correlation with successful orthodontic and surgical facial outcomes. The traits we use were described in detail by Arnett and Bergman in 1993.^{1,2} We ask three questions relative to each trait:

1. What is the quality (good or bad) of the existing facial trait? For instance, how is the upper lip positioned in profile: protrusive, normal, or retrusive?
2. How will orthodontic tooth movement to correct the bite affect the existing trait (positively or

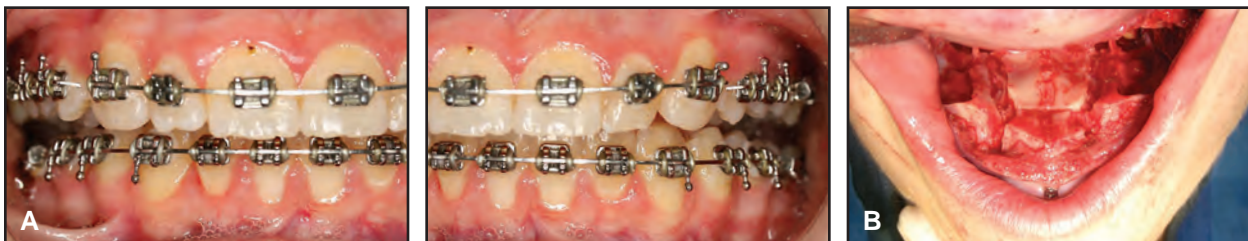

Fig. 1 A. Hanging posterior maxillary lingual cusp tips produced with presurgical orthodontic arch development and excessive labial crown torque. Multisegment maxillary surgery was required to upright posterior segments and establish occlusion. **B.** Photograph of nasal floor during surgery shows 8mm of expansion at osteotomy level and 0mm of expansion at dental level, resulting in unesthetic advancement of nasal base.

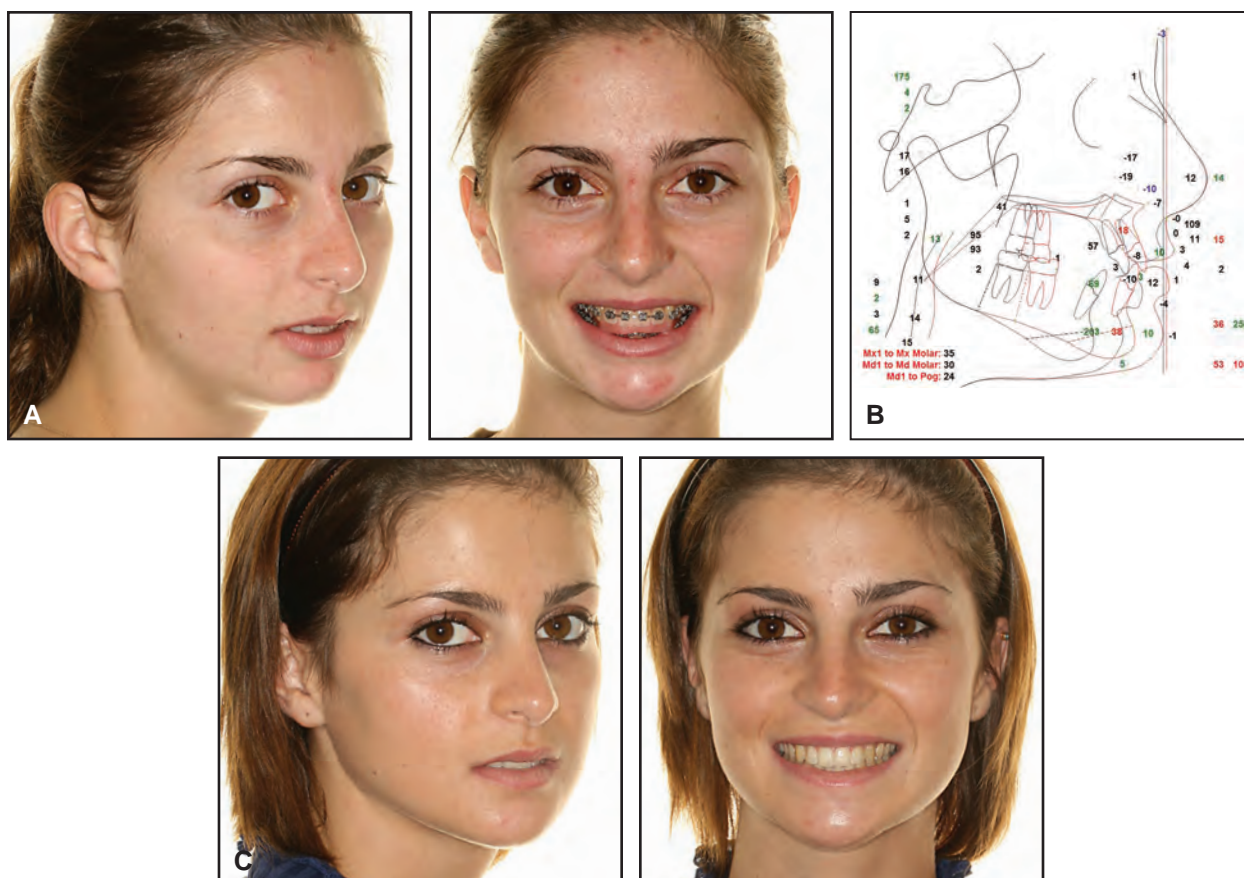


Fig. 2 A. 19-year-old female patient with open, unesthetic buccal corridors, nasal prominence, chin recession, and lack of mandibular angle and body definition. Facial and cephalometric examination revealed maxillary retrusion, mandibular retrusion, and steep occlusal planes. B. Esthetic cephalometric treatment plan involved bimaxillary surgical advancement with counterclockwise flattening of occlusal planes. C. Buccal corridors filled by maxillary advancement and lowering of occlusal plane (no surgical maxillary expansion). Esthetic chin projection produced by bimaxillary counterclockwise advancement without isolated chin augmentation. Note post-surgical harmony between lower facial third, nasal projection, and chin projection and excellent definition of mandibular angles and body.

negatively)? If orthodontic tooth movement results in unacceptable facial balance or facial esthetic decline or leaves sleep apnea symptoms untreated, surgery is indicated. An example of a negative orthodontic effect is when the upper incisors are retracted to correct overjet, but unacceptable upper lip retraction results.

3. When surgery is necessary, which surgery (maxillary, mandibular, or both) will normalize negative facial traits and maintain positive traits while correcting the bite and the airway?

Answering these three questions allows us to develop the ideal treatment plan, as determined by the facial examination. Orthodontic tooth movement alone may produce a satisfactory occlusal and facial correction; if not, then surgery of one or both jaws may be necessary.

Step 3: Esthetic Cephalometric Treatment Planning

After documentation of clinical facial traits,

the treatment plan is further clarified with esthetic cephalometric treatment planning as described by Arnett and Gunson.³⁻⁵ Four treatment plans are attempted for each patient: orthodontics alone, orthodontics plus mandibular surgery, orthodontics plus maxillary surgery, and orthodontics plus surgery on both jaws. The treatment option that corrects the occlusion while optimizing facial balance and the airway is selected.

Esthetic cephalometric planning for orthognathic surgery involves seven substeps:

1. Maxillary incisor angulation to the maxillary occlusal plane (orthodontic tooth movement)
2. Mandibular incisor angulation to the mandibular occlusal plane (orthodontic tooth movement)
3. Overbite correction (may be obtained with substeps 1 and 2)
4. Overjet correction (may be obtained with substeps 1 and 2)
5. Esthetic anteroposterior and vertical maxillary incisor positioning (may be obtained with substeps 1 and 2 or maxillary surgery)

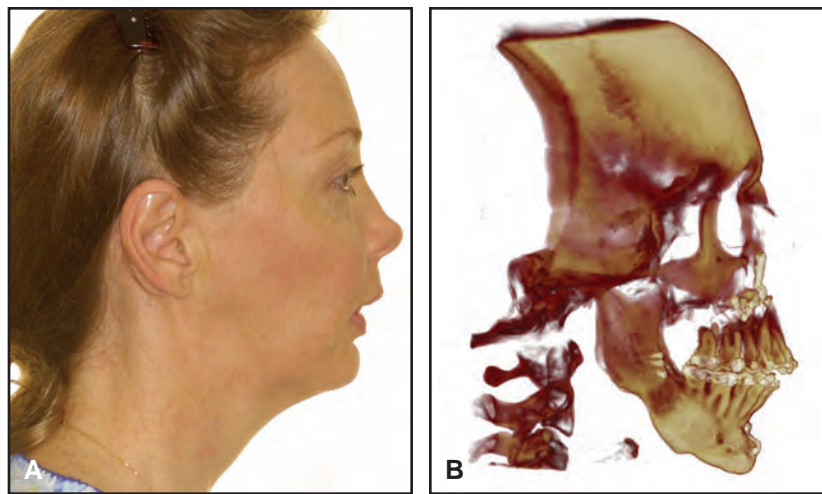

Fig. 3 A. Adult female patient who presented to our office after undergoing upper jaw, lower jaw, and chin augmentation surgeries. Chief dental complaint was “bad bite”; facial complaints included nasal base fullness, upturned nasal tip, straight upper lip, lower lip retrusion, deep labiomental fold, and recessive chin. **B.** Three-dimensional skeletal image after bimaxillary surgery in which jaws were rotated clockwise as part of surgical plan to avoid counterclockwise mandibular advancement. Surgery resulted in Class II anterior open bite and maximum projection of ANS, which led to nasal base fullness, upturned nasal tip, and straight upper lip. Mandibular advancement was also diminished, requiring large genioplasty that produced deep labiomental fold and still failed to normalize chin projection.

6. Occlusal plane manipulation to produce esthetic anteroposterior positions of the nasal base and chin (requires two-jaw surgery)

7. Chin osteotomy when necessary (only after steps 1-6)

Substeps 1 and 2 have been described above under orthodontic incisor positioning; the normal ranges for the upper and lower incisors to the upper and lower occlusal planes are 54-60° and 61-68°, respectively. If orthodontic completion of these substeps corrects the overjet and overbite and provides acceptable facial esthetics, and if a normal airway exists, then surgery is not necessary.

If an overjet abnormality still exists after substeps 1 and 2, treatment proceeds to substeps 3 and 4. In these substeps, the occlusion is positioned in a Class I relationship, and the overbite and overjet are corrected by surgery of the lower, upper, or both jaws.

Substep 5 is utilized when the face is still imbalanced or the airway is still compromised. This maxillary surgery positions the maxillary incisors anteroposteriorly and vertically as indicated by facial needs, providing ideal anteroposterior support of the lip with 3-4mm of incisor exposed beneath the lip.

Substep 6 alters the maxillary and mandibular occlusal planes, based on esthetic and airway needs. The maxillary incisor position, as set in substep 5, acts as the center of rotation for the occlusal plane. The posterior occlusal plane is moved either superiorly or inferiorly, depending on nasal base and chin projection needs. When ideal esthetics are achieved, the maxillary occlusal

plane is usually between 93° and 98° to the true vertical line, which is a line perpendicular to natural head position as described by Arnett and colleagues.³ Flattening the occlusal plane into the normal range maximizes chin projection without the need for substantial, unattractive chin augmentation (Fig. 3). Additionally, a normal occlusal plane prevents the excessive nasal base fullness that can occur when the occlusal plane is steepened with traditional posterior maxillary impaction.

Using a dental mirror, the clinician can measure the need for additional support or projection behind the upper lip and at the nasal base in substeps 5 and 6 (Fig. 4). Unlike published hard-to-soft-tissue movements, this simple mirror advancement test is a valuable tool for predicting individual soft-tissue responses to maxillary advancement.

The last step in cephalometric treatment planning is to assess the chin position. The chin (Pog') is esthetically ideal when it is within -3 ± 2.5 mm of the true vertical line.³ If the chin is either retrusive or protrusive after substeps 1-6, a genioplasty can be performed in substep 7 to obtain esthetic chin balance.

Conclusion

Using this three-step clinical and cephalometric diagnosis and treatment planning approach, the orthodontist and oral surgeon can reliably produce bite correction, facial balance, and airway patency (Fig. 5).

ACKNOWLEDGMENTS: The authors thank Dr. Richard P. McLaughlin for his assistance with preparation of this material.

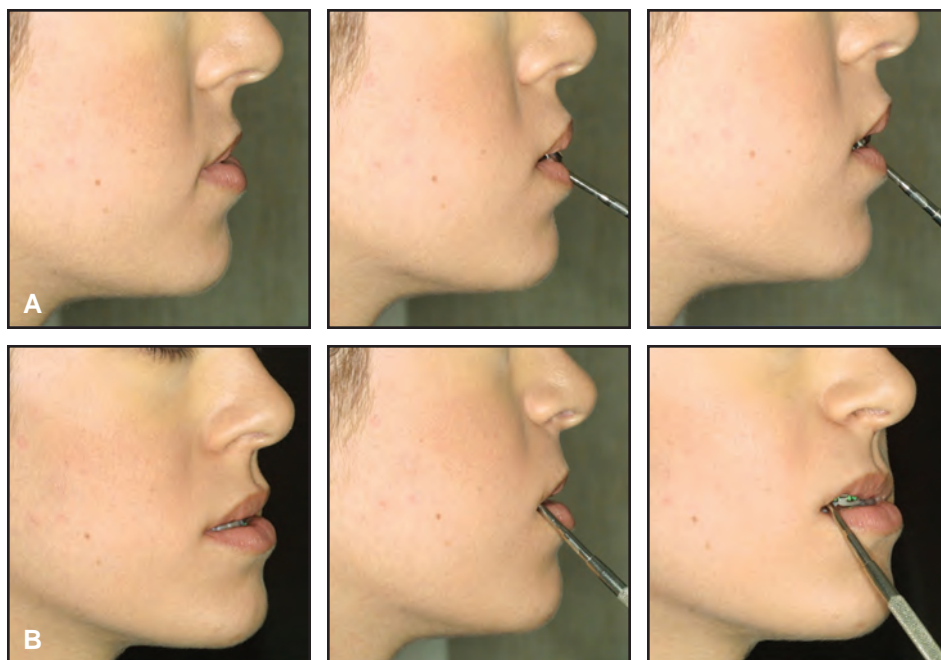

Fig. 4 A. Dental mirror advancement test, upper lip: dental mirror is held behind upper lip and pulled forward until desired support or esthetic change is achieved. Distance from front of mirror to central incisor labial surface equals required amount of anteroposterior maxillary advancement. **B.** Dental mirror advancement test, nasal base: dental mirror is held at nasal base with face relaxed; mirror is then pulled forward into nasal base until esthetic fullness is produced. Distance from front of mirror to mucosa over bone equals required esthetic advancement of maxillary surgery at nasal base.

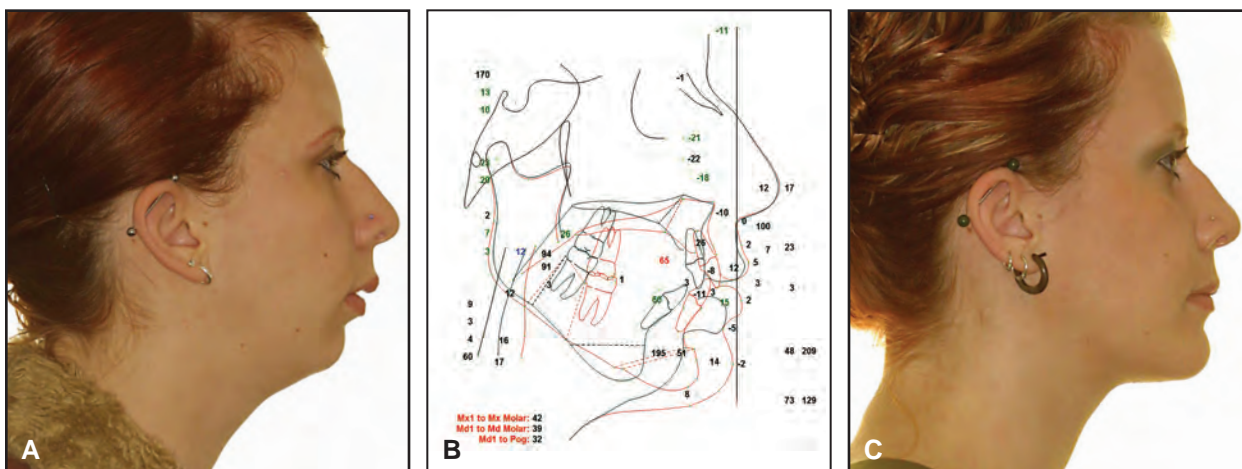


Fig. 5 A. Facial examination in natural head position, seated condyle (first tooth contact), and relaxed lip position reveals extreme nasal projection, thick upper lip, lower lip retrusion, and lack of throat length. **B.** Esthetic cephalometric treatment plan shows occlusal correction, esthetic facial balance, and enlarged airway by means of bimaxillary counterclockwise advancement. Planned 7mm maxillary advancement at lip was determined using dental mirror test (Fig. 4A). After completion of substeps 1-6, 3mm genioplasty was required (substep 7) to provide adequate chin projection. **C.** Normal facial appearance produced by bimaxillary counterclockwise advancement based on occlusal, facial, and airway planning.

REFERENCES

1. Arnett, G.W. and Bergman, R.T.: Facial keys to orthodontic diagnosis and treatment planning—Part I, *Am. J. Orthod.* 103:299-312, 1993.
2. Arnett, G.W. and Bergman, R.T.: Facial keys to orthodontic diagnosis and treatment planning—Part II, *Am. J. Orthod.* 103:395-411, 1993.
3. Arnett, G.W.; Jelic, J.S.; Kim, J.; Cummings, D.R.; Beress, A.; Worley, C.M.; Chung, B.; and Bergman, R.T.: Soft tissue cephalometric analysis: Diagnosis and treatment planning of dentofacial deformity, *Am. J. Orthod.* 106:239-253, 1999.
4. Arnett, G.W. and Gunson, M.J.: Facial analysis: The key to successful dental treatment planning, *J. Cosmet. Dent.* 21:20-33, 2005.
5. Arnett, G.W.; Gunson, M.J.; and McLaughlin, R.P.: Three-dimensional facial treatment planning, in *Distraction Osteogenesis of the Facial Skeleton*, ed. W.H. Bell and C.A. Guerrero, B.C. Decker, Hamilton, Ontario, 2007, pp. 1-10.